This is an open-access article distributed under the terms of the Creative Commons Attribution License, which permits unrestricted use, distribution, and reproduction in any medium, provided the original author(s) and source are credited.

ISSN: 0974-8369

Biology and Medicine

International, Open Access

Available online at: www.biolmedonline.com

This article was originally published in a journal by AstonJournals, and the attached copy is provided for the author's benefit and for the benefit of the author's institution, for commercial/research/educational use including without limitation use in instruction at your institution, sending it to specific colleagues that you know, and providing a copy to your institution's administrator.

All other uses, reproduction and distribution, including without limitation commercial reprints, selling or licensing copies or access, or posting on open internet sites, your personal or institution's website or repository, are requested to cite properly.

Biology and Medicine

Zharmenov *et al.*, Biol Med (Aligarh) 2015, 7:2
http://www.biolmedonline.com

Research Article Open Access

Use of Relaparoscopy in Treatment of Post-Operative Complications

S.M. Zharmenov, S.M. Abuov, R.B. Kalymbetov, T.S. Zhorayev, A.E. Iglikova*

Kazakh Medical University of Continuing Education, 34, Manasa Street, Almaty 050057, Kazakhstan

Abstract

We present our experience of videoendoscopic technologies in treatment of post-operative complications in 98 patients. The outcomes of treatment in 185 patients with post-operative intra-abdominal complications were reviewed. Depending on the method of repeated surgery used, the patients were divided into two groups. The first group consisted of 98 patients to whom relaparoscopy was applied to correct post-operative complications, and the second group consisted of 87 patients to whom conventional relaparotomy was applied. The mortality in the groups amounted to 2.1% and 10.3%, respectively. The post-operative complications were distributed as follows: 67 cases of peritonitis (36.2%), 18 cases of early intestinal obstruction (9.7%), 17 cases of abdominal cavity abscesses (9.2%), 54 cases of bile leakage (29.2%), 27 cases of post-operative bleeding (14.6%), 2 cases of fluid accumulations in abdominal cavity (1.1%). Laparoscopy was the final method of treatment of post-operative complications in 95.9% of patients of the first group. During laparoscopy, it was established that four patients had the actual indications for laparotomy.

Keywords

Post-operative complications; Relaparoscopy; Relaparotomy; Treatment efficiency

Introduction

In spite of permanent development of surgical technologies and use of new surgical treatment methods, high risk of post-operative abdominal complications still remains. The use of endovideosurgical intervention gives a number of advantages as compared with conventional operative intervention, and when required, allows to dynamically check the intra-abdominal environment condition and to perform medical care.

The problem is laparoscopic operative interventions in the abdominal cavity affected by adhesive process resulting from previous surgeries. To extend the opportunities of safe use of laparoscopy, it is necessary to improve diagnostics and techniques. In spite of many problems, the prospects of using laparoscopic intervention for diagnostics and treatment of post-operative complications are obvious. Laparoscopic surgery is a promising method, which requires development, detailed research, improvement of surgical techniques, and comparison with similar upfront surgery.

Currently, minimally invasive techniques are increasingly used in urgent surgeries because they allow decreasing the injury caused by surgeries, and at the same time, increasing the accuracy of diagnostics of acute surgical diseases of the abdominal cavity [1-4]. As medical procedures develop and experience accumulates, many surgeons become more interested in videolaparoscopy during post-operative period. A repeated videolaparoscopy is required for post-operative abdominal complications, which amount to 4-25.8% of all cases in urgent surgery [5-7]. The main cause of failures in treatment of effects of post-operative intra-abdominal complications is the untimely diagnostics of the complications and late repeated intervention [8-10]. Thus, the need for timely diagnostics of this pathology is very urgent. Any novelties in the diagnostics and treatment of post-operative complications which allow identifying and treating any complication timely and with the least injuries deserve the closest attention.

The reserve for improvement of the quality of the surgical treatment of post-operative complications is laparoscopy, which allows to establish the diagnosis as soon as possible, and when possible, to arrange less traumatic intervention [11-14].

The goal of this study is to improve the outcomes of treatment of abdominal post-operative complications based on endo-surgical techniques.

Materials and Methods

The outcomes of treatment were reviewed for 185 patients aged 15-75 (100 males and 85 females), who had surgery on abdominal cavity and retroperitoneal space organs, and who had intra-abdominal complications during post-operative period: the first group (main, 98 patients), where minimally invasive techniques were used; and the second group (control, 87 patients), where relaparotomy was used.

Results and Discussion

In our own studies, the most often cases are post-operative intestinal obstructions and abdominal cavity abscesses. Taking into account post-operative peritonitis, most complications are of infectious nature. Laparoscopic surgeries for general or localized forms of peritonitis were performed in 36 patients (Table 1), and laparotomies were performed in 31 patients. The localized peritonitis was identified in 20.7%, and general peritonitis was identified in 79.3% of cases. In 34 patients, the causes of peritonitis were eliminated, and laparoscopic sanation was performed. In two patients, during laparoscopy, a laparotomy was performed. The mortality rate during post-operative period was 5.5% and 29.0% in the first and the second groups, respectively, which coincides with the study of Zaverniy [3].

The abdominal cavity abscesses were mainly localized in subphrenic (44.1%) and subhepatic space (32.2%). The interloop abscesses were identified less frequently (15.3%), as well as small pelvis abscesses (3.3%), or abscesses of other localization (5.1%). A laparoscopic sanation was applied to 9 out of 17 patients with abdominal cavity abscesses,

***Corresponding author:** Iglikova AE, Kazakh Medical University of Continuing Education, 34, Manasa Street, Almaty 050057, Kazakhstan

Received: April 17, 2015; **Accepted:** May 9, 2015; **Published:** Jun 2, 2015

Citation: Zharmenov SM, Abuov SM, Kalymbetov RB, Zhorayev TS, Iglikova AE, (2015) Use of Relaparoscopy in Treatment of Post-Operative Complications. Biol Med (Aligarh) 7(2): BM-097-15, 3 pages.

Copyright: © 2015 Zharmenov *et al*. This is an open-access article distributed under the terms of the Creative Commons Attribution License, which permits unrestricted use, distribution, and reproduction in any medium, provided the original author and source are credited.

Causes of complications during early post-operative period	Number of patients	
	Absolute number	%
Peritonitis	36	36.7
Bile leakage	21	21.4
Bleeding	12	12.3
Early adhesive intestinal obstruction	11	11.2
Abscesses	9	9.2
Fluid accumulations	9	9.2
Total	**98**	**100**

Table 1: Complications during early post-operative period

Causes	Number of patients	
	Absolute number	%
Injured liver surface	3	14.3
Failure of outer drainage in obstructive jaundice	5	23.8
Failure of cystic duct stump	11	52.4
Remaining cavities after echinococcectomy	2	9.5
Total	**21**	**100**

Table 2: Bile leakage causes

and in seven cases it was effective. A laparotomy was required for two patients with general subhepatic abscesses. The data obtained proves again that the laparoscopic method may be a good alternative to open surgical intervention. The possibility to perform complete sanation of the abscess cavity and walls (removal of necrotic detritus and fibrinous accumulations from the walls of pyogenic coat) is an essential advantage of laparoscopy as compared with paracentesis drainage performed under ultrasound guidance [6], while keeping minimum invasion and injury as compared with conventional surgical treatment.

The bile leakage during post-operative period was identified in 54 patients. Among the causes of the leakage, prevailing are injuries of extrahepatic bile ducts. Laparoscopic interventions were performed urgently due to development of biliary peritonitis. The localized accumulations of bile (biliomas) were identified in 11 patients, and the general biliary peritonitis was identified in the other 10 patients (Table 2).

In all the cases, laparoscopy was the final method of diagnosis of bile leakage, which allowed eliminating it immediately. One should agree with the opinion of a number of specialists stating that in case of bile leakage, the contra-indication to a laparoscopic intervention is the injury of extrahepatic bile ducts [6], and thus, no patients with such diagnosis were included in the first group.

The laparoscopic hemostasis was successfully performed in all 12 patients, who had surgery to that end (Figure 1).

It should be stated that in case of suspected post-operative bleeding, the indications for surgery must be strictly restricted. We believe that any laparoscopic intervention is counter-indicated for the cases of unstable blood circulation, or evidences of profuse bleeding. In 8 out of 12 patients of the group, bleeding stopped spontaneously by the time of relaparoscopy. In four patients, bleeding was identified right after surgery, which, to some extent, facilitated the repeated intervention. The bleeding source is easily identified when blood is aspirated and simultaneously removed from the surrounding tissues by a manipulator. Thus, the surgical tactics depend on the nature of injury of vessel and bleeding intensity. Often, in case of moderate bleeding from the liver bed, it is sufficient to use spray coagulation. If it is ineffective, it is possible to sew on hemostasis sponge or to sew the cystic bed by atraumatic needle. In case of insufficient clipping of the cystic artery, hemostasis was achieved by catching the vessel by a dissector. After assessment of anatomic relations, clipping was performed under the clear visual guidance. Since recently, Liga Sure vessel sealing generator has been successfully used by us to stop bleeding in seven bleeding patients. In general, the ways of laparoscopic hemostasis are similar to those of conventional manipulations.

In 16 out of 18 patients, intestinal obstruction was of adhesive nature. In three patients, the obstruction was caused by incarceration of small intestine in the window of parietal peritoneum, intestine torsion, and anamostosis stricture. Most frequently, synechias were observed after surgeries performed for destructive appendicitis accompanied by peritonitis (16 patients). A laparoscopic intervention was performed for intestinal obstruction in 11 patients (Figure 2).

Adhesiolysis was successful in four cases. In case of the other three patients (3.06%), there were considerable technical problems caused by the presence of dense, immovable conglomerate, which required a laparotomy. The dynamic form of obstruction was identified during relaparoscopy in four patients (4.01%), which allowed avoiding relaparotomy. The total length of stay of the first group patients in the hospital was 7.2 days as compared with 15.4 days for the second group (control). The use of relaparoscopy in treatment of post-operative complications allowed us to avoid using narcotic analgesics, and to apply non-steroid anti-inflammatory drugs only when necessary during the first 2-3 days. During the first two days, the second group patients received narcotic analgesics due to heavy pain syndrome, and later, they kept receiving non-steroid anti-inflammatory drugs during 5-7 days.

Minimally invasive surgical interventions performed under ultrasound guidance play a very important role in the diagnostics and treatment of extra-organ localized fluid accumulations in the abdominal cavity. Our study involved two patients with fluid accumulations, which

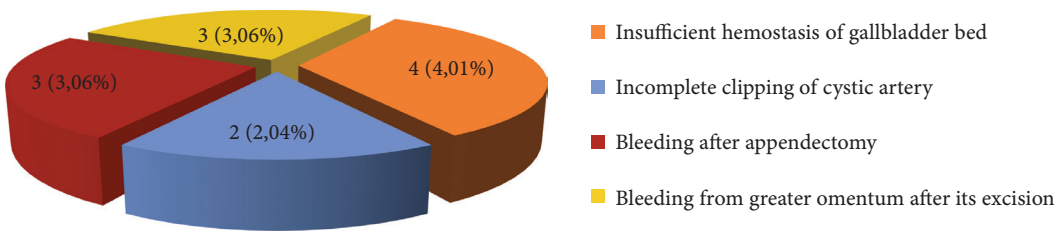

Figure 1: Bleeding causes

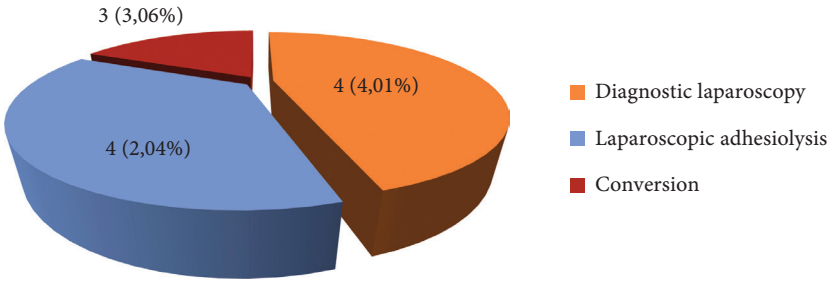

Figure 2: Surgical interventions for early post-operative intestinal obstruction

were identified during ultrasound examination. During laparoscopy, in all the cases, the abdominal cavity was successfully sanitized.

There were no deaths in the cases of abscesses of abdominal cavity, bile leakage, bleeding, and intestinal obstruction.

Conclusion

Videolaparoscopy allows diagnosing post-operative intra-abdominal complications timely. Laparoscopy is efficient and safe in treatment of post-operative complications. While keeping the safety of abdominal wall, the laparoscopic access allows directly visualizing the abdominal cavity, and quickly identifying the complication, and choosing the necessary tactics. Moreover, laparoscopy reduces the rate of complications after the repeated surgery, mortality, and hospital stay length, improves the life quality, soothes pain, and ensures quick return of a patient to his/her usual activities.

References

1. Berezov IuE, Perminova GI (1980) Urgent Laparoscopy in the Nearest Post-operative Period. In the Proceedings of All-Russian Science and Practice Conference of Surgeons, Saratov, p. 25.
2. Dudanov IP, Sobolev VE, Andreev IuV (2007) Laparoscopy in the issue of early post-operative intra-abdominal bleedings. Surgery (6): 30-33.
3. Zaverniy LG (1990) Frequency of intra-abdominal complications and relaparotomies during early post-operative period. Surgery Bulletin (3): 131.
4. Zyubritskiy NM (1989) Methods of recognition of post-operative intra-abdominal complications. Surgery Bulletin (8): 143.
5. Golovkova IG (2006) Role of Laparoscopy in Diagnostics and Treatment of Post-operative Peritonitis in Urgent Abdominal Surgery: Author's Abstract of thesis for the Degree of Candidate of Medical Science, Khabarovsk, p. 25.
6. Khadzhibayev AM, Atadzhanov ShK, Ermetov AT, *et al.* (2007) Laparoscopic interventions in diagnostics and treatment of early post-operative intra-abdominal complications in abdominal surgery. Surgery (8): 48-51.
7. Kriger AG, Shurkalin BK, Glushkov PS, Andreitsev IL (2003) Diagnostics and treatment of post-operative intra-abdominal complications. Surgery (8): 19-23.
8. Strusov VV, Gaidukov VN, Magomedov MG (2002) Relaparoscopy: Concept and algorithm of treatment of post-operative complications of abdominal surgery. Endoscopic Surgery (5): 34-36.
9. Feodorov AV, Chadayev AP, Sazhin AV, Stegniĭ KV, Karlov DI (2005) Relaparoscopy in treatment of post-operative complications. Surgery (8): 80-85.
10. Chernov EV, Kachurin VS, Ushkats AK (2001) On structure of early post-operative intra-abdominal complications. Collection of studies of physicians of the 442nd District Military Clinical Hospital named after Z.P. Solovyev, Saint Petersburg, pp. 16-18.
11. Freys SM, Fuchs KH, Heimbucher J, Thiede A (1994) Laparoscopic adhesiolysis. Surgical Endoscopy 8: 1202-1207.
12. MacSweeney STR, Postlethwaite YC (1994) "Second-look" laparoscopy in the management of acute mesenteric ischaemia. British Journal of Surgery 81: 90.
13. Peitgen K, Nimtz K, Heilliger A, Walz MK (1997) Offen Zugang oder Veress-Nadel bei laparoskopischen Eingriffen? Chirurgie 68: 910-913.
14. Slutzki S, Halpern Z, Negri M, Kais H, Halevy A (1996) The laparoscopic second-look for ischemic bowel disease. Surgical Endoscopy 10: 729-731.

Citation: Zharmenov SM, Abuov SM, Kalymbetov RB, Zhorayev TS, Iglikova AE (2015) Use of Relaparoscopy in Treatment of Post-Operative Complications. Biol Med (Aligarh) 7(2): BM-097-15, 3 pages.

Submit your next manuscript and get the following advantages

Special features:

- 30 days rapid review process
- Quality and quick editorial, review and publication processing
- Indexing at Scopus, EBSCO, ProQuest, Gale Cengage, and Google Scholar etc
- Authors, Reviewers and Editors rewarded with online Scientific Credits
- Better discount for your subsequent articles

Submit your manuscript at: http://www.biolmedonline.com