


eISSN: 09748369

Treatment of open diaphyseal fractures of long bones of the limbs

Biology and Medicine

Research Article



Volume 7, Issue 1, Article ID: BM-065-15, 2015
Indexed by Scopus (Elsevier)

Treatment of open diaphyseal fractures of long bones of the limbs

Azer Jafar Abdullayev*

Department of Travmatology and Orthopaedic, Azerbaijan Medical University, Baku, Azerbaijan.

*Corresponding author

Citation: Abdullayev AJ (2015) Treatment of open diaphyseal fractures of long bones of the limbs. Biol Med 7(1), Article ID: BM-065-15, 6 pages.

Received: 24th Dec 2014; Accepted: 8th Jan 2015; Published: 12th Feb 2015

Abstract

Article presents the results of treatment of patients with open diaphyseal fractures of long bones. There were both men and women among the victims. Patients were divided according to localization and severity of fractures. A comparative study of clinical and radiological results of treatment of patients with various methods was performed. We determined long-term outcomes over 5 yrs. Analysis of the data showed that the use of the device and special ointment of A.D. Abdullayev in open diaphyseal fractures of long bones contributed to the achievement of the best results. Total duration of bone repositioning and hospital stay decreased, there was a complete consolidation of the fracture fragments, and the wounds healed by first intention.

Keywords: Open diaphyseal fractures; external fixator; reposition; ointment of Abdullayev; long-term results; consolidation of the fracture fragments.

Introduction

Modern world is characterized by the rapid development of technology, which leads to a dramatic increase in the number and nature of the injuries [1,2], which in turn requires a change in the principles and tactics of their treatment. There is a tendency to an increase in the number of injuries related to traffic accidents and local wars [3-6].

There are many problems in the treatment of open diaphyseal fractures of the limbs [7-9]. Choosing a method of fracture fixation, prevention of wound infection, primary surgical treatment of injuries, measures against bleeding and hemorrhagic shock, purulent-necrotic complications in soft tissues, reducing the incidence of amputation, selection and use of antibacterial agents, and other problems need to be addressed today [10-12]. Therefore, we have to set a goal to make a comparative analysis of various methods of treatment of open fractures of the limbs to identify the optimal method for clinical use.

Materials and Methods

We performed clinical and radiological study in 234 patients with open diaphyseal fractures

of the extremities admitted to the M. Nagiyev Emergency Hospital in Baku during the period from 1990 to 2010. From these patients there were 180 (76.3%) men, and 54 (23.7%) women. Age of the patient was from 15 to 81 yrs.

There were 51 patients with open fractures of the upper extremities, and 183 patients with an open fracture of the lower extremities. One subject had a fracture of arm and forearm, six subjects had fracture of the femur and tibia bones, and one subject had a hip fracture in both legs and shin fracture in one leg.

The number of patients with polytrauma was 52 (22.2%), patients with arm fractures – 15 (6.0%), forearm – 37 (15.0%), hip – 38 (15.3%), and shin – 158 (63.7%).

According to the classification of V.P. Okhotsky (1) open fractures of the extremities were divided into the following groups: grade 1 fractures (minor wounds that are easily sutured by simple stretching of the wound edges) – 191 (77.0%) patients, grade 2 fractures (wound of the average size with soft tissue damage, a surgeon needs to use relaxation incisions in order to close the fracture fragments) – 37 (15%), grade 3 fractures (ruptures of large areas of soft tissue with bruises – skin grafts are necessary) – 14 (5.6%) patients, and grade 4 fractures (extensive

soft tissue and major vessels damage, violation of vital activity of limbs, traumatic amputation) – 6 (2.4%) patients.

Open fractures were classified according to their cause as follows: 84 (35.8%) – traffic accidents; 75 (32.1%) – fall; 28 (12.0%) – household; 22 (9.4%) patients – manufacturing; 6 (2.6%) – sport; 19 (8.1%) – other reasons. The largest number of open fractures accounts for traffic accidents – 84 (35.8%) patients, especially those involving automobile accidents.

Treatment of open fractures of the limbs was performed by osteosynthesis using an external fixator in 189 (80.8%) patients, and in 45 (19.2%) patients we used the method of metal osteosynthesis.

From the above noted 45 patients that underwent metal osteosynthesis, in 38 ones we performed metal osteosynthesis of the open intramedullary hip fracture. For this purpose, we used compression nail of A.D. Abdullayev (inventor's certificate R 970 029; patent No. 970029, 22.07.1994).

In 164 of 189 patients with open fractures who were treated with the help of external fixation device we used two models of the A.D. Abdullayev apparatus: the Abdullayev apparatus for reposition and fixation of bone fragments (inventor's certificate R 970 028; No. R 970028, 27.06.1994); and the Abdullayev apparatus for osteosynthesis (patent No. 20000097, 24.07.1998). For the treatment of 8 (9.1%) patients we used the Wagner rod device, and in 17 patients (53.4%) – the Ilizarov apparatus.

Clinical Case

Medical case No. 2769. The patient O., 34 yrs old, was admitted in the M. Nagiyev Emergency Hospital in Baku on 23.06.1990 with open fractures of 1/3 diaphyseal part of the bone of the right shoulder and damaged radial nerve. The patient was injured in the traffic accident. The patient was admitted to the hospital for in-patient treatment on the next day after the injury. He underwent clinical, radiological examination, and lab analysis. Osteosynthesis of the humerus was carried out using the Abdullayev apparatus (Figure 1). After applying of the apparatus, radial nerve was released from clamping by bone fragments. After 5 h sensitivity and impaired motor function of the radial nerve were restored. Wounds around the fracture were treated with the ointment of Abdullayev (fractions of naftalan oil and tetracycline). After 6 days the wound healed. The duration of fixation by apparatus was 6 days (Figures 2 and 3).

Results and Discussion

The total duration of hospital treatment of patients was 32 days. Osteosynthesis of open fractures of the long bones of the extremities by the method of external fixation was performed in 189 (80.8%) patients, metal synthesis – in 45 (19.2%). Long-term results of treatment were determined in 110 patients of 234 people treated. We monitored these patients within 5 yrs. As a

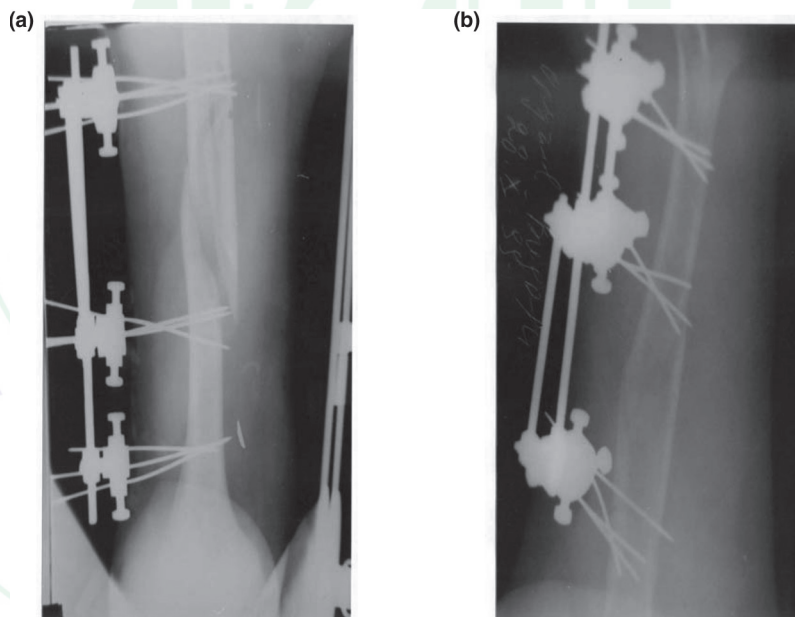
Figure 1: Patient O. with the apparatus of A.D. Abdullayev on the humerus at the beginning of treatment.

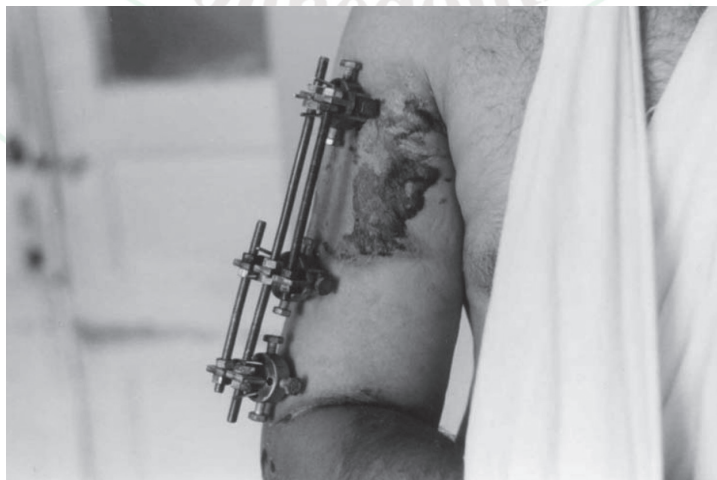

Figure 2: Patient O. with the apparatus of A.D. Abdullayev on the humerus during the treatment.

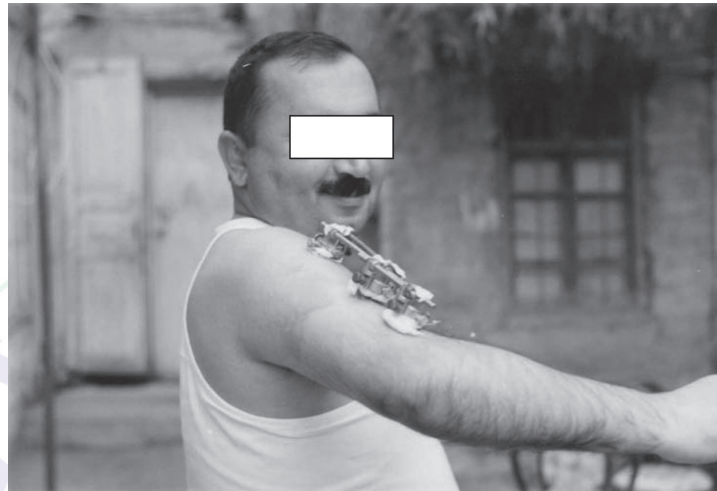

Figure 3: Patient O. Radiography: (a) fixation of displaced fracture of 1/3 of the right humerus using the Abdullayev apparatus; (b) consolidation of fracture fragments, Day 92 of the treatment (end of the treatment).



result, it was found that in 90 (81.8%) of these patients the result of treatment is evaluated as “good”, in 12 (10.9%) – “satisfactory”, and in 8 (7.3%) – “unsatisfactory”. 88 (80.0%) patients returned to their former place of work, 10 (9.0%) patients had to change the scope of their professional activities, and 12 (10.9%) were assigned varying degrees of disability.

Osteomyelitis developed in 8 (3.4%) of 234 patients with open fractures of long bones. The symptoms of the disease were determined in 6 patients, while exacerbation was observed in 2 patients.

In 189 patients with open fractures of long bones, the following devices of external fixation were used: the A.B. Abdullayev apparatus

in 164 (86.8%) patients, the Wagner rod device in 8 (4.2%) patients, and the Ilizarov apparatus in 17 (9.0%) patients.

The results of the treatment of open fractures of long bones by external fixator were followed up for 2 yrs after their removal. The best result was observed in patients who used the A.B. Abdullayev apparatus. In this case a good result was achieved in 93.3% of patients.

51 patients with open diaphyseal fractures of the upper extremities were treated. From them there were 43 (84.3%) men and 8 (15.6%) women. There were 14 patients with a fractured shoulder bone, and there were 37 patients with forearm fractures. In one patient, there was a fracture of both shoulder and forearm bones. In all of these patients we used the Abdullayev apparatus as an external fixator. In two patients the Abdullayev apparatus was used in the shoulder and forearm bones simultaneously. An average duration of fracture fragments fixation was 88 days. An average length of hospital stay of patients was 20 days.

Out of 183 patients with open fractures of the long bones of the lower extremities 138 (75.4%) patients were men, 45 (24.6%) – women. These fractures were divided into the following ones according to the anatomical segments: fracture of femur – 38 cases and shin – 158 cases. Five patients were admitted with open fractures of both hip bones, and 6 patients – with simultaneous fractures of femur and tibia. In one patient, there was a fracture in three anatomical segments: two hips and shin.

According to the classification of V.P. Okhotsky, open fractures of long bones of the lower extremities were divided in the following manner: grade 1 – 149 (75.6%), grade 2 – 31 (15.7%), grade 3 – 12 (6.0%), and grade 4 – 5 (2.5%) patients.

Fixation devices were mounted in all 183 patients admitted to the hospital. The A.B. Abdullayev Apparatus was used for 158 subjects, the Ilizarov apparatus – for 17 patients, and the Wagner rod device – for 8 patients. The average duration of applying external fixation device was 42 days, and the average length of hospital stay – 22 days.

This is stable fixation of fracture fragments that creates optimum conditions for consolidation, wound healing in the area of fracture and prevents infection of wounds. Therefore, choosing the improved methods of osteosynthesis is important in the treatment of open fractures.

In osteosynthesis with an external fixator, it is the duration of surgery that plays a very important role. Thus in combination of open fractures of the extremities and head injury in the state of traumatic shock, especially in case of mass admission of patients, duration of osteosynthesis with an external fixator is of great importance. According to our observations, in contrast to the Ilizarov apparatus the use of Abdullayev apparatus and the Wagner rod device is less traumatic and time consuming.

The mean duration of surgery using the A.D. Abdullayev apparatus is 12 ± 2 min, the Wagner rod device – 25 ± 5 min, and the apparatus of Ilizarov – 75 ± 5 min.

Unlike with the Wagner rod device, a physician is able to fixate fracture fragments with the help of the Abdullayev apparatus by using several different rods. Besides the Abdullayev apparatus is functional and enables repositioning of the fracture fragments after the surgery. So it may be used in different fractures.

In contrast to the Ilizarov apparatus, the Abdullayev apparatus is small, lightweight, and convenient for the patient. It can be placed in the patient's body without problems for a long time, and does not interfere with gymnastic exercises, which prevents the reduction of the consolidation of fracture fragments.

In order to assess the long-term results of treatment, we followed up patients from the 1st to the 5th year. As a result we concluded that 93.3% of their treatment was completed as “good” and “satisfactory” result.

We performed clinical study of the ointment of Abdullayev (patent No. R 990103, 13.03.1998) consisting of a mixture of naphthenic hydrocarbons presented in Naftalan oil and tetracycline.

The Abdullayev ointment was applied in 63 patients for the treatment of open fractures wounds by topical application. We applied the A.D. Abdullayev apparatus in order to fix the fracture fragments.

According to the classification of Okhotsky V.P., there were 48 (76.2%) patients with grade 1 open fractures, 12 (19.0%) patients with grade 2 open fractures, and 3 patients (4.8%) with grade 3 open fractures. An average duration of fixation using the A.D. Abdullayev apparatus in all patients was 3.4 months. In all patients, we observed synostosis and full restoration of limb function.

In nine patients (14.3%) with open fractures, we observed suppurative complications.

Table 1: Complications observed after mounting an external fixator.

Type of complication	A.D. Abdullayev Apparatus		Wagner rod device		Ilizarov apparatus	
	Number of complications	%	Number of complications	%	Number of complications	%
Inflammation of the rod or soft tissue around the rod	4	12.1	2	25.0	20	42.6
Osteomyelitis near to the rod or in the areas where it passes	-	-	-	-	1	2.1
Superficial wounds fester	1	3.0	3	37.5	6	12.8
Deep wounds fester	1	3.0	1	12.5	10	21.3
Osteomyelitis	1	3.0	2	25.0	5	10.6
Secondary displacement of fragments	-	-	-	-	1	2.1
Synostosis failure or false joints	-	-	1	12.5	1	2.1
Improper synostosis	1	3.0	2	25.0	2	4.3
Contracture	1	3.0	1	12.5	4	8.5

Observations showed that purulent complications can be caused by the absence of radical surgery or its delayed implementation.

Thus, during the treatment of 63 patients with open fractures of limbs positive effects without septic complications were observed in 85.7% of cases. In all patients, we performed cytological examination by the method of A.V. Nikolaev (method of printing smear).

Complications observed in patients after mounting an external fixator are presented in Table 1.

As can be seen from Table 1, the most common complication is inflammation of the rod or soft tissue around the rod. This complication was observed in 26 patients (29.5%). The use of the Ilizarov apparatus led to such complications in every second case. The use of the A.D. Abdullayev apparatus as compared to the results of the Ilizarov apparatus application reduced the rate of inflammation near to the rod by 12.1%.

This is explained by the fact that the rods of the A.D. Abdullayev apparatus are firmly attached to each other at the distance of 1.0-1.5 cm from the bone. This provides a stable rigid fixation.

The cause of such complications has been established. Studies have shown that inflammation of the soft tissue around the rod may occur due to the following reasons:

1. Non-compliance with the rules of aseptic and antiseptic.
2. Burns of soft tissues obtained while the rod is passed through the cortical layer of bone.

These complications occur when the doctor does not make pauses during rod passing by an electric drill.

3. If you violate stable fixation in the apparatus. Soft tissue displacement along the rods creates conditions for invasion of infection.

We did not observe any specific complications associated with construction of the A.D. Abdullayev apparatus.

Conclusion

Based on the results of clinical and radiographic studies of open fractures of long bones, we conclude that the external fixator of A.D. Abdullayev shows good clinical results. The treatment of patients with open diaphyseal fractures of long bones using the combination of the Abdullayev apparatus and new ointment on the basis of Naftalan oil (Azerbaijan), in comparison with other methods (Wagner, Ilizarov), has a number of advantages. It reduces the average duration of fracture fragments fixation, bone consolidation, and duration of hospital treatment. Patients did not develop infection complications, and wounds healed by the first intention. Long-term results of the treatment showed that 93.3% of patients had good outcomes. For this reason the modified method of A.D. Abdullayev can be recommended for the routine use in clinical practice for the treatment of open fractures of the long bones of the extremities.

References

1. Sharief Z, Sharif Kh, Ali A, Abdunabi M (2011) High energy tibial fractures managed by external fixators. *Journal of Bone and Joint Surgery – British Volume* 93-B: 105-109.
2. Werner CM, Pierpont Y, Pollak AN (2008) The urgency of surgical débridement in the management of open fractures. *Journal of the American Academy of Orthopaedic Surgeons* 16(7): 369-375.
3. Vijay C, Mahendra Kumar KL, Manjappa CN (2011) Management of open type IIIA and type IIIB fractures tibia external fixation. *The Internet Journal of Orthopedic Surgery* 18: 2. <http://connection.ebscohost.com/c/articles/61294607/management-open-type-iiia-type-iiib-fractures-tibia-lrs-external-fixator>. (29.12.2014).
4. Robinson CM, Stone OD, Murray IR (2011) Proximal humeral fractures due to blunt trauma producing skin compromise. *Journal of Bone and Joint Surgery – British Volume* 93-B: 1632-1637.
5. Zalavras CG, Marcus RE, Levin LS, Patzakis MJ (2007) Management of open fractures and subsequent complications. *The Journal of Bone and Joint Surgery – American Volume* 89: 884-885.
6. Tabatabai S, Mehdinasab SAH, Hossaini E (2009) Continuing or converting external Fixation for the treatment of open tibial fractures. *Journal of Bone and Joint Surgery – British Volume*, 91-B: 461-466.
7. Singh S, Lo S, Soldin M (2012) Soft tissue management of open distal third tibial fractures: free versus local flap cover. *Journal of Bone and Joint Surgery – British Volume* 94-B: 149-153.
8. Reynders P (2010) Factors affecting rates of infection and prolonged bone healing in 821 operative treated isolated tibial shaft fractures. *Journal of Bone and Joint Surgery – British Volume* 92-B: 355-359.
9. Friedrich JB, Katolik LI, Hanel DP (2011) Reconstruction of soft-tissue injury associated with lower extremity fracture. *Journal of the American Academy of Orthopaedic Surgeons* 19: 81-90.
10. Warner CML, Pierpont Y, Pollak AN (2008) The urgency of surgical debridement in the management of open fractures. *Journal of the American Academy of Orthopaedic Surgeons* 19: 81-90; 16: 369-375.
11. Stuart Melvin J, Domborski DG, Torbert JT, Kovach SJ, Esterhas JL, *et al.* (2010) Open tibial shaft fractures: 2-d definitive management and limb salvage. *Journal of the American Academy of Orthopaedic Surgeons* 18: 108-117.
12. Rambani R, Sharma H, Sood A (2010) Validity of six-hour rule in grade 3 open fractures. *Journal of Bone and Joint Surgery – British Volume* 92-B: 557-563.