

Early Diagnosis and Treatment of Squamous Cell Carcinoma—A Case Comparison Highlighting its Importance

Peraza L. Alberto¹ and Harvey P. Kessler^{2*}

¹Professor of Oral Pathology and Oral Surgery, Department of Oral Surgery and Oral Pathology, Pontificia Universidad Javeriana, Carrera 7ma. número 40-62 Bogota, Colombia

²Professor of Pathology, Department of Diagnostic Sciences, Texas A&M University Baylor College of Dentistry, Dallas, TX 75246, United States of America

*Corresponding author: Harvey P. Kessler, DDS, MS, Department of Diagnostic Sciences, Texas A&M University Baylor College of Dentistry, Dallas, TX 75246, United States of America, Tel: 214-828-8116; Fax: 214-828-8306; E-mail: hkessler@bcd.tamhsc.edu

Received date: December 10, 2015; Accepted date: January 11, 2016; Published date: January 14, 2016

Copyright: © 2016 Alberto PL, et al. This is an open-access article distributed under the terms of the Creative Commons Attribution License, which permits unrestricted use, distribution and reproduction in any medium, provided the original author and source are credited.

Abstract

The importance of early diagnosis and treatment of oral squamous cell carcinoma in insuring an optimum patient outcome is emphasized by comparing and contrasting the clinical presentation, diagnosis, treatment and follow-up of two patients who presented initially with fairly equivalent mucosal lesions but followed different treatment paths. The divergence of patient outcomes is directly linked to the time difference in microscopic examination.

Keywords: Early diagnosis; Squamous cell carcinoma

Introduction

Prompt intervention in the management of early stage oral squamous cell carcinoma (OSCC) after a diagnosis has been established by biopsy is the most reliable way to achieve the best possible outcome for patient survival and function [1-3].

Oral squamous cell carcinoma (OSCC) is considered to be the result of a multistep process which involves a number of aberrant genetic events. Oral cavity squamous cell carcinoma (OSCC) is the sixth most common malignancy worldwide, with nearly 300,000 new cases annually. Tobacco smoking and the heavy use of alcohol are probably the best known risk factors for this disease [4], but it is important to mention that around 4%-10% of patients with OSCC are not exposed to these risk factors [5,6].

Recent studies have suggested the importance of evaluation by general dental practitioners, which doesn't take substantial additional time to adequately examine the oral mucosa, particularly in geriatric patients and high-risk patients. Within the dental health care setting, this would seem to be a feasible and theoretically cost-effective strategy when incorporated into the regular recall visit. Thus, patients with potentially malignant oral lesions, mostly oral epithelial dysplasia, can quickly be referred to a secondary or tertiary multidisciplinary clinic for evaluation and treatment by specialists in oral and maxillofacial surgery, oral medicine and oral pathology [6-8].

For the oncologic patient, the prognostic evaluation and therapeutic planning of OSCC is mainly based on clinical staging using the TNM (T, tumor size; N, regional lymph node involvement; M, metastases) classification [7]. However, there is still much debate concerning the best way to approach neck disease in the case of early-stage lesions (T1 and T2) [8]. Part of the problem with a "wait and see" approach is that patients affected by OSCC with clinically negative nodes at the time of presentation (N0) have a high risk of harboring occult node metastases [9]. In these cases, the only definitive way to prove the presence or

absence of metastasis is by postoperative histologic examination of lymph nodes, necessitating a neck dissection as a component of the treatment plan [9]. Nevertheless, despite all the new modern medical diagnostic and therapeutic services, the 5-year survival rate ranges from 30% to 80% in varying regions of the world, but the overall mortality rate for OSCC remains high, at approximately 50% [8,9]. In the United States every year almost 25,000 patients are diagnosed with OSCC and more than five thousand will die as a consequence of the disease. The main problem with the TNM system is that it is often a poor predictor of patient outcomes [10,11]. This is believed to be due to the failure of the TNM system to take into consideration the tumor biology and molecular characteristics in addition to the tumor's anatomic localization. Applying tumor biology and molecular information to the classification process may prove useful in complementing the TNM staging [12].

The early diagnosis of OSCC has a fundamental role in its prognosis, and when the patients are diagnosed at later stages, they have higher mortality rates and the treatment is less effective [8]. Although this is well known, there have been few investigations into how patient profiles correlate with the diagnostic delay of this tumor. It has been suggested that the delay in diagnosis of OSCC is mainly caused by patient neglect [10]. Furthermore, owing to the asymptomatic nature of oral cancer at its early stage, as will be demonstrated in this case presentation, patients with this disease for several reasons don't seem to seek medical advice in the early stages of their disease compared with patients suffering from cancer at other sites [11]. This accounts for why some patients have a better outcome than others. In recent decades, attention has been focused on a handful of biomarkers frequently associated with the disease. Among these, the most frequently associated biomarker is p53, a tumor suppressor gene, and the mutation of p53 has been considered to be the most common genetic feature in head and neck cancers [13]. Factors that have been associated with affecting the clinical behavior of OSCC include epidemiologic parameters (age, sex, race, alcohol and/or tobacco intake), clinical parameters (T classification, TNM stage, site of the lesion) and histologic parameters (perineural invasion, intravascular

invasion, inflammatory response to the tumor, grade of the neoplasm, pattern of invasion and tumor thickness) [14].

Several studies evaluated tumor thickness, which can be considered an objective parameter of the depth of invasion within the connective tissue. The increasing depth of invasion and the microvascular proliferation caused by neoplastic growth might enhance proximity to blood vessels and lymphatics, thus facilitating the tumor's ability to metastasize. Moreover, it has been observed that it is more difficult for tumor emboli to form in the small-caliber lymphatics of superficial areas than in the wider lymphatics of deeper tissue [15-17].

Materials and Methods

This is a report of two cases detailing diagnosis and treatment of clinically similar lesions in two female patients who came to the Dental Comprehensive Center in Acarigua Venezuela for evaluation. The cases highlight the significant difference in outcome when comparing early diagnosis and treatment with a delay in diagnosis.

Case 1

An 82 year old female patient was referred for an oral white lesion that had been treated in the past with oral antibiotics on two separate occasions by other dental services, without a clear diagnosis. The lesion presented as a white papulo-plaque on the left mandibular masticatory mucosa in an edentulous area (Figure 1). The patient did not have a removable prosthesis replacing the missing teeth in the area. The lesion was 0.5 cm in diameter, thick, indurated, asymptomatic and of approximately 5 months duration.

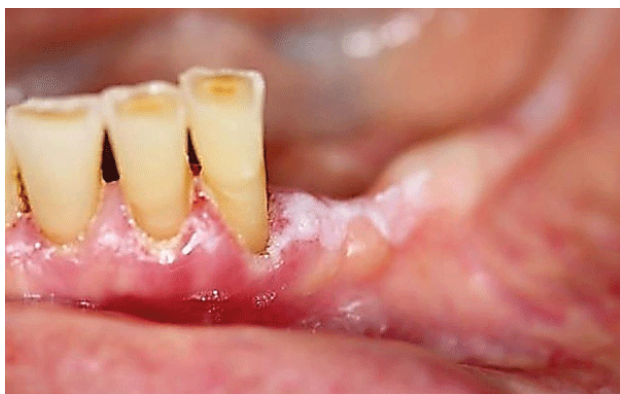

Figure 1: Clinical picture of the first patient. The white lesion extended almost one centimeter distal to the mandibular left lateral incisor.

Biopsy revealed microinvasive squamous cell carcinoma. Histologically, epithelial pleomorphism, dyskeratosis, nuclear variability and mitotic activity were observed. Invasion into the connective tissue was evident (Figure 2).

The lesion was classified as a T1 neoplasm and the patient was referred to the oncologic service. She was treated with conservative

surgery including a 1cm margin of normal appearing soft tissue and bone, followed by 12 radiotherapy sessions to a total of 50 Gray. The lesion didn't invade vascular components or extend into the bone, on the histopathologic exam. After treatment the patient experienced some xerostomia and gingival recession. She was followed clinically in the dental clinic after that for more than two years without evidence of recurrent disease.

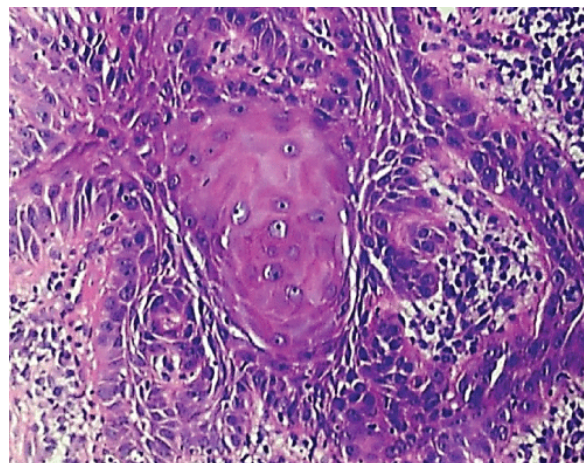


Figure 2: Histopathologic features of lesion in the first patient.

Two and a half years later, re-evaluation of the patient revealed a white papular lesion over the edentulous area (Figure 3). The lesion was indurated and had been present for two weeks. Excisional biopsy was performed including a 1 cm margin of surrounding normal appearing tissue.

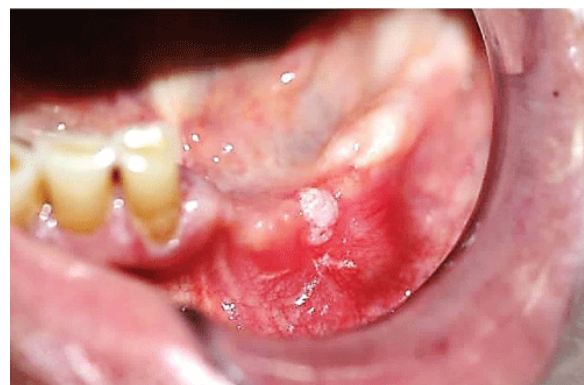

Figure 3: Clinical picture of the recurrent lesion in first patient two years after the initial squamous cell cancer diagnosis.

Histopathological study showed recurrent invasive moderately differentiated squamous cell carcinoma (Figure 4), this time with vascular and bone invasion.

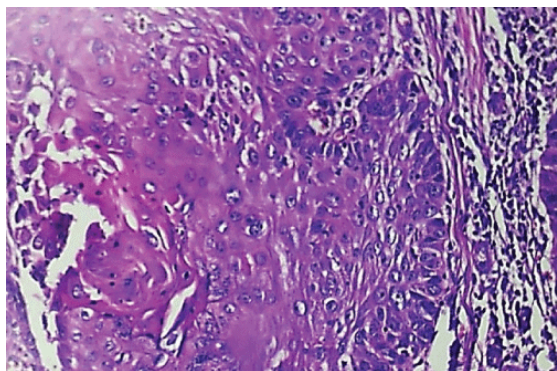


Figure 4: Histology of the second excisional biopsy of the first patient.

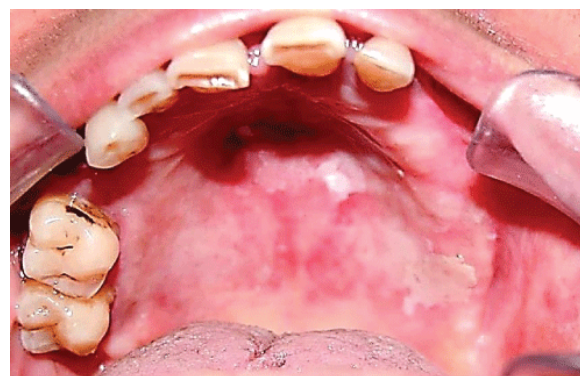

Figure 6: Clinical presentation of the second patient who declined biopsy initially, with a maculo plaque lesion, that wouldn't rub-off, was of unknown duration, unilateral and asymptomatic.

The patient didn't demonstrate clinically positive neck nodes and she was sent again to the head and neck oncologic department for additional treatment. The patient began her treatment almost 8 months later, receiving radiotherapy of 6600 cGy in 33 sessions, chemotherapy with cetuximab 400 mg/m² intravenous the first day, followed by the same medication at a lower dose of 250 mg/m² once per week for 5 weeks. When the treatment was completed in April 2014, the patient presented level two mucositis, necessitating a gastrotomy for adequate nutrition, as she had lost more than 45 pounds. A Computed Tomography survey revealed no evidence of malignancy and she was sent for a new biopsy which proved negative for cancer (Figure 5).

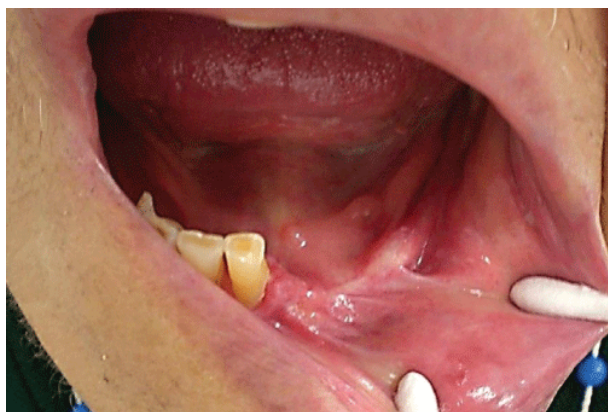

Figure 5: Clinical appearance of the patient after completion of oncology therapy, one year after removal of recurrent lesion.

Two and a half years after initially refusing a biopsy, the patient returned for evaluation. The remaining maxillary teeth had been extracted in the interim. Examination revealed a mucosal tumor of the alveolar crest extending into the buccal vestibule and onto the palate (Figure 7). The lesion was indurated and the patient noted some discomfort. The lesion infiltrated bone and extended to the maxillary sinus. A biopsy was taken for diagnosis.

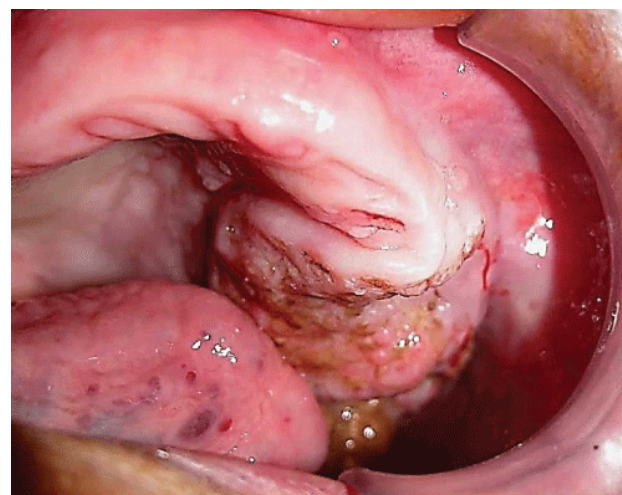


Figure 7: Increased size of the tumor, with loss of teeth. The lesion was now indurated and more extensive.

Case 2

A 79 year old female patient presented with two lesions in the hard palate. The lesions were present on the left side in an edentulous area (Figure 6). The missing teeth had been replaced by a poorly adapted removable prosthesis. The lesion was a white maculo-plaque measuring 0.8 cm. It was firm to palpation, asymptomatic and of unknown duration. The patient refused biopsy at this time.

The histology (Figure 8) revealed invasion of pleomorphic epithelial cells, increased nuclear cytoplasmic ratio, mitosis, dyskeratosis, keratin pearls, invasion into muscle tissue in the vestibule, nerve infiltration, vascular and bone infiltration. Clinically positive lymph nodes in the neck were not detected. The patient was sent to the Oncology department for treatment. The patient developed lung metastasis that proved difficult to treat and the patient passed away in March 2014.

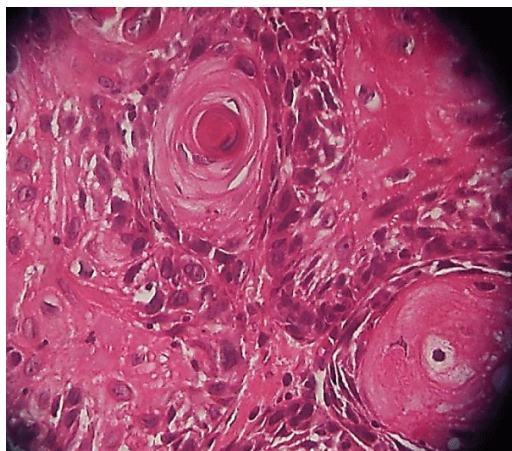


Figure 8: Histopathological features of the squamous cell carcinoma of the hard palate tumor.

Discussion

Oral cancer is the sixth most common malignancy worldwide, with a yearly incidence of more than 284,000 cases until 2005 [18]. The survival rate of patients with oral squamous cell carcinomas (OSCCs) has not increased substantially over the last several decades. Despite advances in surgery, radiotherapy and chemotherapy, the overall average 5-year survival rate for patients still remains at approximately 50% over the past 30 years. This survival rate is lower than that of laryngeal or nasopharyngeal carcinoma. It is also in contrast to many other types of body cancer that have a better outcome. One hypothesis for this difference is a lack of training that might increase clinical recognition of malignancy among dentists when compared to the training received by physicians. Also patients may be unaware of the risk of premalignant lesions or be unable to recognize small suspicious lesions in the mouth. For female patients the necessity for an annual cytology examination by the Medical Gynecologic Services, or Dermatologic examination when skin lesions are noticed is well recognized, but there's still a taboo when it comes to oral lesions [19-21]. In fact, the poor prognosis associated with oral cancer is mostly accounted for by the fact that most lesions are diagnosed at a late stage of the disease. Patients usually delay seeking professional advice on average for up to 3 months after having become aware of any oral symptom that could be linked to oral cancer [22]. Studies about the relationship between HPV infection and patient survival have led to different conclusions. Although no association with survival was found in the present cases, a few earlier investigators found that HPV-infected OSCC patients had a better survival rate than those with HPV-negative tumors. In cases where adequate surgery is completed with clear margins, and no other risk factors are present, no additional treatment is typically needed. However, what constitutes a "close margin" (defined as invasive carcinoma within a certain distance from the specimen edges) is institution-specific, ranging from 1 to 5 mm. Despite the differences between centers in the definition of a "close" margin, retrospective analyses suggest that a close margin heralds increased locoregional failure. Perineural invasion (PNI), which was seen in Case 2 of this report, is another important factor that impacts prognosis. PNI is a tropism of tumor cells for nerve bundles in the surrounding tissues. PNI is a form of metastatic tumor spread similar

to but distinct from vascular or lymphatic invasion that hinders the ability to establish local control of a malignancy. Neoplastic cells can travel along nerve tracts far from the primary lesion such that, at surgery, distant PNI is typically undetected and therefore the likelihood of recurrence is increased. As a result, these tumors can exhibit pain and persistent growth with a long clinical course and late onset of metastases, a pattern that has been observed in neurotropic tumor types such as melanoma, prostate and pancreatic cancer and the salivary gland malignancies adenoid cystic carcinoma and polymorphous low-grade adenocarcinoma.

Conclusion

Treatment for squamous cell carcinoma has become increasingly more sophisticated yet a large number of cases are still diagnosed at higher stage, hindering long term survival. The key to prolonged survival is early diagnosis, which will require a concerted effort by both dental and medical health care providers to adequately screen the oral cavity for the earliest changes associated with malignancy, with subsequent biopsy confirmation. With this approach, seamless patient management, from the mildest premalignant change to treatment of frank malignant disease, can best be accomplished. In the cases reported here, the patients presented with roughly equivalent initial clinical lesions, and the benefits of early diagnosis and prompt treatment are emphasized when compared to delaying initial diagnosis. So the emotional decision to avoid or delay oral health care when it is necessary will constitute the difference between an almost normal quality of life after prompt treatment or a difficult way of life when the disease is invasive or disseminated.

Conflict of Interest

Authors do not have any conflicts of interest relative to the contents of this article.

References

1. Ganly I, Patel S, Shah J (2012) Early stage squamous cell cancer of the oral tongue—clinicopathologic features affecting outcome. *Cancer* 118: 101-115.
2. Ho MW, Field EA, Field JK, Risk JM, Rajlawat BP, et al. (2013) Outcomes of oral squamous cell carcinoma arising from oral epithelial dysplasia: rationale for monitoring premalignant oral lesions in a multidisciplinary clinic. *Br J Oral Maxillofac Surg* 51: 594-599.
3. Pytynia KB, Grant JR, Etzel CJ, Roberts DB, Wei Q, et al. (2004) Matched-pair analysis of survival of never smokers and ever smokers with squamous cell carcinoma of the head and neck. *J Clin Oncol* 22: 3981-3988.
4. Sargeran K, Murtomaa H, Safavi SM, Vehkalahti MM, Teronen O (2008) Survival after diagnosis of cancer of the oral cavity. *Br J Oral Maxillofac Surg* 46: 187-191.
5. Brocklehurst P, Kujan O, Glennly AM (2010) Screening programmes for the early detection and prevention of oral cancer. *Cochrane Database Syst Rev* 11: CD004150.6.
6. Speight PM, Palmer S, Moles DR, Downer MC, Smith DH, et al. (2006) The cost-effectiveness of screening for oral cancer in primary care. *Health Technol Assess* 10: 1-144, iii-iv.
7. Kalavrezos N, Scully C (2015) Mouth Cancer for Clinicians Part 4: Risk Factors (Traditional: Alcohol, Betel and Others). *Dent Update* 42: 644-646, 648-50, 653-4.
8. Ross GL, Soutar DS, MacDonald DG, Shoaib T, Camilleri IG, et al. (2004) Improved staging of cervical metastases in clinically node-negative

- patients with head and neck squamous cell carcinoma. *Ann Surg Oncol* 11: 213-218.
9. Fakih AR, Rao RS, Borges AM, Patel AR (1989) Elective versus therapeutic neck dissection in early carcinoma of the oral tongue. *Am J Surg* 158: 309-313.
 10. Howaldt HP, Kainz M, Euler B, Vorast H (1999) Proposal for modification of the TNM staging classification for cancer of the oral cavity. *DOSAK. J Craniomaxillofac Surg* 27: 275-288.
 11. Guggenheimer J, Verbin RS, Johnson JT, Horkowitz CA, Myers EN (1989) Factors delaying the diagnosis of oral and oropharyngeal carcinomas. *Cancer* 64: 932-935.
 12. Pentenero M, Gandolfo S, Carrozzo M (2005) Importance of tumor thickness and depth of invasion in nodal involvement and prognosis of oral squamous cell carcinoma: a review of the literature. *Head Neck* 27: 1080-1091.
 13. Oliveira LR, Ribeiro-Silva A, Costa JP, Simões AL, Matteo MA, et al. (2008) Prognostic factors and survival analysis in a sample of oral squamous cell carcinoma patients. *Oral Surg Oral Med Oral Pathol Oral Radiol Endod* 106: 685-695.
 14. Onercl M, Yilmaz T, GedikoÄŸlu G (2000) Tumor thickness as a predictor of cervical lymph node metastasis in squamous cell carcinoma of the lower lip. *Otolaryngol Head Neck Surg* 122: 139-142.
 15. Kurokawa H, Yamashita Y, Takeda S, Zhang M, Fukuyama H, et al. (2002) Risk factors for late cervical lymph node metastases in patients with stage I or II carcinoma of the tongue. *Head Neck* 24: 731-736.
 16. Rahima B, Shingaki S, Nagata M, Saito C (2004) Prognostic significance of perineural invasion in oral and oropharyngeal carcinoma. *Oral Surg Oral Med Oral Pathol Oral Radiol Endod* 97: 423-431.
 17. Hayashi T, Ito J, Taira S, Katsura K (2001) The relationship of primary tumor thickness in carcinoma of the tongue to subsequent lymph node metastasis. *Dentomaxillofac Radiol* 30: 242-245.
 18. Parkin DM, Bray F, Ferlay J, Pisani P (2005) Global cancer statistics, 2002. *CA Cancer J Clin* 55: 74-108.
 19. Mashberg A (2000) Diagnosis of early oral and oropharyngeal squamous carcinoma: obstacles and their amelioration. *Oral Oncol* 36: 253-255.
 20. Reiter R, Gais P, Steuer-Vogt MK, Boulesteix AL, Deutschle T, et al. (2009) Centrosome abnormalities in head and neck squamous cell carcinoma (HNSCC). *Acta Otolaryngol* 129: 205-213.
 21. Siebers TJ, Bergshoeff VE, Otte-Höller I, Kremer B, Speel EJ, et al. (2013) Chromosome instability predicts the progression of premalignant oral lesions. *Oral Oncol* 49: 1121-1128.
 22. Gómez I, Warnakulasuriya S, Varela-Centelles PI, López-Jornet P, Suárez-Cunqueiro M, et al. (2010) Is early diagnosis of oral cancer a feasible objective? Who is to blame for diagnostic delay? *Oral Dis* 16: 333-342.