

Diagnosis and Treatment of Cardiac Myxoma-Short Term Clinical Analysis of 14 Cases in a Single Hospital

Mohammed Firoj Khan* and Xian-En Fa

Department of Cardiovascular Surgery, 2nd Affiliated Hospital of Zhengzhou University, Zhengzhou, Henan, China

*Corresponding author: Mohammed Firoj Khan, Department of Cardiovascular Surgery, 2nd affiliated hospital of Zhengzhou University, Zhengzhou, Henan, China, 450014, Tel: 008613027787275; E-mail: falishakhan72@yahoo.com

Received date: June 24, 2016; Accepted date: July 18, 2016; Published date: July 25, 2016

Copyright: © 2016 Khan MF, et al. This is an open-access article distributed under the terms of the Creative Commons Attribution License, which permits unrestricted use, distribution and reproduction in any medium, provided the original author and source are credited.

Abstract

Objective: Short term clinic-pathological analysis of intracardiac myxoma in 14 cases

Material and Methods: From January-2016 to May-2016, 14 patients, 5 males and 9 females, aged 22 ~ 71 mean age (45.1 ± 13.3) years were admitted in our department of cardio-vascular surgery, the second affiliated hospital of Zhengzhou university. All the patients were diagnosed to have myxoma by transthoracic echocardiography. Myxoma was in different positions in the heart, 9 cases in left atrium, 2 cases in right atrium, 2 cases in left ventricle and 1 case in right ventricle. All the patients were performed open heart surgery via midsternal incision under cardiopulmonary bypass with slight hypothermia and myxomas were excised successfully.

Result: Myxoma was found most commonly in the left atrium. All the 14 patients were performed open heart surgery as to remove the myxomas. 1 patient died due to acute renal failure and low cardiac output syndrome at 24hr postoperative with perioperative mortality rate of 7.14%. All other patients had uneventful recovery and discharged at postoperative 10-19 days with average hospital stay time of 13.76 days.

Conclusion: Myxoma is the most common tumor of the heart which is most frequently located in the left atrium. Careful surgical excision and meticulous removal of myxomatous debris with proper perioperative management is the choice of treatment with minimal early and late morbidity as well as mortality.

Keywords Intracardiac myxoma; Myxomatous; Transthoracic echocardiography

Introduction

Myxoma is a myxoid tumor of primitive connective tissue. Myxomas are polypoid, round, or oval. They are gelatinous with a smooth or lobulated surface and usually are white, yellowish, or brown. Atrial myxomas are the most common primary heart tumors in all age groups accounting for one-third to one-half of cases at postmortem and for about three quarter of tumors treated surgically [1]. Most atrial myxomas arise from atrial septum, usually from the region of the limbus of fossa ovalis. About 10% have other sites of origin, particularly posterior wall, anterior wall and appendages in order of frequency [2]. About 90% of myxomas are solitary and pedunculated. Most myxomas (75-85%) are in the left atrium. About 25% found in right atrium. Right atrial myxomas tend to be more solid and sessile than left atrial myxomas, with a wider attachment to the atrial wall or septum. They can be multicentric (within a single chamber) or biatrial.

Over 72% of primary cardiac tumors are benign. In adults, the majority of benign lesions are myxomas [3,4]. Although atrial myxomas are typically benign, local recurrence due to inadequate resection or malignant change has been reported. Occasionally, atrial myxomas recur at a distant site because of intravascular tumor embolization. The risk of recurrence is higher in the familial myxoma syndrome [5].

Tumors vary widely in size, ranging from 1 to 15 cm in diameter, and weighing between 15 and 180 g. Symptoms from a cardiac myxoma are more pronounced when the myxomas are left-sided, racemosus, and over 5 cm in diameter [6]. About 35 percent of myxomas are friable or villous, and these tend to present with emboli. Larger tumors are more likely to have a smooth surface and to be associated with cardiovascular symptoms [7].

Material and Methods

The clinical data

A total of 14 cases, 5 males and 9 females, aged 22 ~ 71 (45.1 ± 13.3) years. 9 cases in the left atrium, 2 cases in right atrium, 2 cases in left ventricle and 1 case right ventricle. Out of 9 left atrial myxomas, 7 were pedunculated and attached to the atrial septum, while 2 cases attached to the posterior wall of the left atrium. 2 cases in right atrium were attached near the opening of inferior vena cava below the opening of coronary sinus. 2 cases in the left ventricle located near the apex attached to a septal pedicle. One of tumor sized 101 mm × 70 mm × 30 mm, weight about 100 g, almost filled the entire left ventricular cavity.

Clinical manifestation

Symptoms of palpitations and shortness of breath (SOB) in 14 cases, malaise in 11 cases, hepato-splenomegaly and edema of lower extremity in 7 cases. There was a history of syncope in 4 cases, haemoptysis in 2 cases, cough in nine cases, and anemia in three cases complicated by renal failure. Digital clubbing was found in 2 cases. Hypertension found in 1 case. There were three cases of embolism. On Physical examination, apical heart murmur was found in eight cases, including one case with obvious plop sound after the first heart sound.

Diagnosis

X-rays showed different degrees of pulmonary congestion and cardiac enlargement. Normal ECG in five cases while remaining patients have, left atrium, left and right ventricular hypertrophy with other cardiac disorders such as altered cardiac function and heart rhythm, different types of arrhythmias. All patients were performed transthoracic echocardiography and confirmed by color doppler examination that there are myxomatous lesions of varying sizes in different positions within the heart. The lump moved with the heartbeat, especially the left atrial myxoma moves towards left ventricle during diastole through mitral valve and returned to left atrium during systole. The lump in the right atrium moves along the tricuspid valve during systole and returned to right atrium during systole as in the left side. The tumor in the ventricle moves towards the outflow tract during systole (Figure 1).

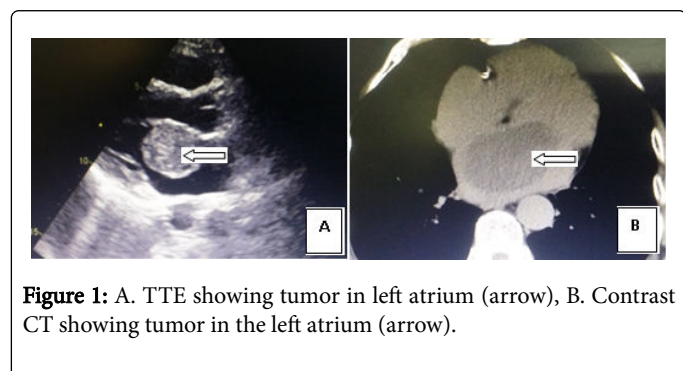


Figure 1: A. TTE showing tumor in left atrium (arrow), B. Contrast CT showing tumor in the left atrium (arrow).

Surgical methods

All the patients had taken consent signs for surgery. Median sternotomy and usual cardiopulmonary bypass were established. Out of 14 cases, 1 case of left ventricular mass needed hypothermic CPB and remaining 13 cases were performed under normal CPB without hypothermia. Cardiac arrest was done by using warm blood cardioplegic solution through aortic root infusion after the aortic clamp. After the cardiac arrest, the right atrium was felt with fingers to find the position of myxoma in right atrium. With proper observation, incised the right atrium and the tumors were exposed. Finding the pedicle, the lesions were excised along with the pedicle (Figure 2).

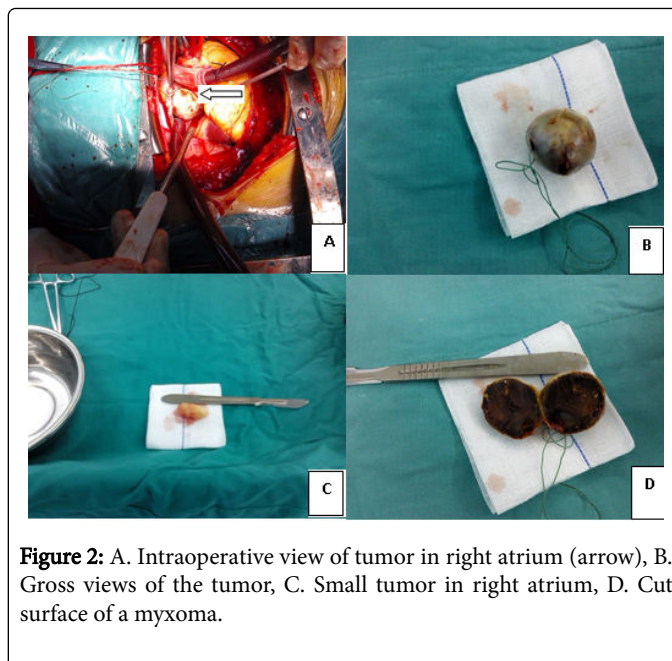


Figure 2: A. Intraoperative view of tumor in right atrium (arrow), B. Gross views of the tumor, C. Small tumor in right atrium, D. Cut surface of a myxoma.

For the mass in the left atrium, after opening the right atrium and retracted to expose interatrial septum, digital feeling of septum with the toughest area confirmed the site of attaching the pedicle were performed. Using this site, we incised the septum and the tumor was completely excised as above. Myxoma in the left ventricular apex was challenging. We used transatrial septal approach to remove the lesion. Heart chambers were repeatedly washed. Right ventricular myxoma began to remove immediately after establishing CPB to prevent pulmonary incarceration and thrombosis.

Surgical result

All 14 cases underwent surgery. One case developed low cardiac output syndrome, acute renal failure and died 24hr after surgery. Perioperative mortality was 7.14%. One case had postoperative nodal rhythm, which after two months restored to sinus rhythm. All other 13 cases remained well and had uneventful recovery with proper postoperative management. Hospital stay time was 10-19 days, average 13.76 days. At the time of discharge, cardiac function of 1 case was grade II and 13 cases were grade I. All the patients were asked to follow up after 3 months.

Pathological results

The cut surface of the tumors showed pale-gray and red tissues confirmed myxomatous changes.

Discussion

Myxomas are most common primary cardiac tumors comprising 30% of all the primary tumors of the heart and the incidence of cardiac myxoma at autopsy is being 0.0017% - 0.28% [8]. Most cases of atrial myxoma are sporadic and the exact etiology is unknown. About 7% are familial [9] and have autosomal dominant trait in which tumors are multiple and found usually in the ventricles [10]. Constitutional include myalgia, fever, fatigue, weight loss, muscle weakness, arthralgia and chest pain which are reported in about 20% of patients and around 20% of patients are asymptomatic [11]. Severe dizziness or syncope is

found in about 20% of patients due to obstruction of mitral valve by the tumor [12]. Atrial myxomas are more common in left atrium and produce symptoms when they reach to 70 g while in the right side shows symptoms when the tumor becomes twice this size. Symptoms are produced by mechanical interference with cardiac function or embolization. Being intravascular and friable, myxomas account for most cases of tumor embolism. Embolism occurs in about 30-40% of patients. The site of embolism is dependent upon the location (left or right atrium) and the presence of an intracardiac shunt.

Jong-Won Ha and associates reported a more frequent occurrence of systemic embolism in polypoid tumors as compared to round (58% vs 0%) [13]. The myxomas are vascular tumors and may be neovascularized by a branch of a coronary artery [14]. Recently, a case of hemorrhage in a left atrial myxoma was reported [15].

The lack of specific, sensitive clinical manifestations of this disease and inability to diagnose by the physician leads to the delayed diagnosis and sudden death. The diagnosis of the disease by cardiac color Doppler examination is the most appropriate non-invasive technique [16] where various chambers of the heart are to be carefully examined to prevent any misdiagnosis. Those Myxomas located in special parts such as in the left atrial appendage, etc., detection by conventional transthoracic ultrasound easily missed the lesion. Using, transesophageal ultrasound can clearly specify the tumor location, size and position of pedicle [17]. Sometimes diagnosis can be supplemented by CT or MRI to confirm the lesion.

Atrial myxoma can be successfully removed [18-22]. Surgical resection is an effective choice of treatment for this disease, the mortality is low but may cause sudden death and therefore, early diagnosis is very important. Bahnson and Newman reported [20] the earliest surgical approaches to myxomas by removing a myxoma from the right atrium via right anterior thoracotomy using a short period of caval obstruction at normothermia. Craford [19] successfully excised a myxoma from left atrium using cardiopulmonary bypass whereas Coates et al. [22] reported a successful excision of a right atrial myxoma.

For patients with the advanced age should consider coronary angiography to exclude any associated coronary artery disease. Some study has been reported that out of 24 cases of cardiac myxoma, five cases were diagnosed coronary heart disease by preoperative angiography and performed CABG during the surgery to excise myxoma [23]. Pediatric cardiac myxoma usually cause fatigue, difficulty breathing, wheezing, heart failure, often misdiagnosed as infective endocarditis. Myxoma induced cerebral aneurysm and myxomatous metastasis can mimic vasculitis or endocarditis [24]. Infectious cardiac myxoma resembles infective endocarditis. Diagnosis depends mainly on suspicion of the disease and parallel color Doppler examination can confirm the lesion. Infectious endocarditis with poor efficacy after medical treatment should be suspected of myxomatous disease [25].

Carney syndrome is an autosomal dominant genetic disease with multiple tumors in skin, mucous membrane, adrenal gland; thyroid gland with cardiac myxoma [26]. Carney complex is a rare genetic disorder characterized by multiple benign tumors (multiple neoplasia) most often affecting the heart, skin and endocrine system and abnormalities in skin coloring (pigment) resulting in a spotty appearance to the skin of affected areas. Benign tumors of connective tissue (myxomas) are common in individuals with Carney complex and, most often, are found in the heart where they can potentially

cause serious, life-threatening complications including stroke valvular obstruction or heart valve. A wide variety of endocrine abnormalities potentially can occur in Carney complex affecting a variety of glands. Additional tumors include myxomas affecting the skin and nerve sheath tumors (schwannomas). Skin pigment abnormalities include tiny flat (freckle-like) black or brown spots (multiple lentiginos) and small, blue or bluish-black spots (blue nevi). It is a familial cardiac myxoma which constitutes 7% of all myxoma [27]. Family history is advisable to check all family members, with a view to early detection of such syndrome [28].

Age is not a contraindication for surgery, Fuwa [29] reported one case of 77-year-old woman whose left atrial myxoma was successfully removed, Talmor [30] reported one case of successful right ventricular myxoma excision in five months old, postoperative results were good. The surgery is safe, with an early postoperative mortality of 2.2%. Some authorities believe resection should be performed immediately after the diagnosis is made. Postoperative atrial fibrillation is seen in 23-33% of patients [31,32]. In a series of 91 cases of atrial myxoma, postsurgical neurologic complications were seen in 3% of cases, and the exploration for bleeding was required in 5% of cases [32].

For the tumors in right atrium or right ventricle, cardiopulmonary bypass begins immediately after pulmonary artery occlusion to prevent pulmonary embolism. Left ventricular myxoma should be removed through the right atrium - atrial septal path, try to avoid cutting right ventricular wall, so as to prevent affecting left ventricular systolic function. Surgical assistant can squeeze the heart apex to expose the left ventricular tumor through the mitral valve. It has been reported [33] the removal of the tumor on the atrial route has good exposure. Patients with concurrent coronary heart disease may simultaneously perform CABG. Myxoma induced damage to the heart valves caused valve dysfunction and valve replacement surgery can also be done at the same time [34].

To avoid recurrence, the tumor should be removed together with its pedicle along with the endocardial tissue attached to the pedicle. Surgery should be careful and check all four-chamber of heart to prevent the omission [35]. Rinse thoroughly each chamber of the heart before the end of surgery to prevent embolism. Recurrence of the disease is low, but there is a family history of recurrence, especially young people. So, long-term follow-up by color Doppler is the best way to prevent recurrence [7].

Limitations

Our study had a small sample size and a short period of time.

Conclusion

Myxoma is the most common tumor of the heart which is most frequently located in the left atrium. Most of the patients had complains of cardiovascular symptoms. Transthoracic echocardiography is the most useful diagnostic tool which can reveal the lesions well. Careful surgical excision and proper removal of myxomatous debris is the choice of treatment. Proper perioperative management can minimize early and late morbidity as well as mortality.

References

1. Fauci B, Hauser K, Jameson L (2001) Disorders of cardiovascular system: Cardiac tumours, cardiac manifestations of systemic disease (15thedn) *Harrison's Principles of Internal Medicine*, pp. 1372-74.
2. McAllister HA Jr (1979) Primary tumours of the heart and pericardium. *Pathol Annu* 14: 325.
3. Yu K, Liu Y, Wang H, Hu S, Long C (2007) Epidemiological and pathological characteristics of cardiac tumors: a clinical study of 242 cases. *Interact Cardiovasc Thorac Surg* 6: 636-639.
4. Amano J, Kono T, Wada Y, Zhang T, Koide N, et al. (2003) Cardiac myxoma: its origin and tumor characteristics. *Ann Thorac Cardiovasc Surg* 9: 215-221.
5. Larsson S, Lepore V, Kennergren C (1989) Atrial myxomas: results of 25 years' experience and review of the literature. *Surgery* 105: 695-8.
6. Obrenović-Kirčanski B, Mikić A, Parapid B, Djukić P, Kanjuh V, et al. (2013) A 30-year-single-center experience in atrial myxomas: from presentation to treatment and prognosis. *Thorac Cardiovasc Surg* 61: 530-6.
7. Pinede L, Duhaut P, Loire R (2001) Clinical presentation of left atrial cardiac myxoma. A series of 112 consecutive cases. *Medicine (Baltimore)* 80: 159-172.
8. Vassiliadis N, Vassiliadis K, Karkavelas G (1997) Sudden death due to cardiac myxoma. *Med Sci Law* 7: 76-78.
9. Bulkley BH, Hutchins GM. Atrial myxomas: a fifty year review (1979) *Am Heart J* 7 97: 639-43.
10. Amir O, Merdler A, Shiran A (2001) Bilateral atrial myxomas associated with hyperpigmented skin lesions. *N Engl J Med* 344: 938-9.
11. Burke A, Judy J, Virmani R (2008) Cardiac Tumors: an update. *Heart* 94: 117-123.
12. Kapoor MC, Singh S, Sharma S (2004) Resuscitation of a patient with giant left atrial myxoma after cardiac arrest. *Journal of cardiothoracic and vascular anesthesia* 18: 769-771.
13. Ha JW, Kang WC, Chung N (1999) Echocardiographic and morphologic characteristics of left atrial myxoma and their relation to systemic embolism. *Am J Cardiol* 83: 1579-1582.
14. Hasdemir H, Alper AT, Arslan Y, Erdinler I (2011) Left atrial myxoma with severe neovascularization: role of preoperative coronary angiography. *Turk Kardiyol Dern Ars* 39: 163-5.
15. Park J, Song JM, Shin E, Jung SH, Kim DH, et al (2011) Cystic cardiac mass in the left atrium: hemorrhage in myxoma. *Circulation* 123: e368-9.
16. Miralles A, Bracamonte L, Rabago G (1989) Heart myxoma-Surgical treatment. *Rev Esp Cardiol* 42: 666-672
17. Dujardin KS, Click RL, Oh JK (2000) The role of intraoperative transesophageal echocardiography in patients undergoing cardiac mass removal. *Am Soc echocardiogr* 13: 1080-1083
18. Scannel JG, Brewster AWR, Bland F (1956) Successful removal of a myxoma from the left atrium. *New England J A Med* 254: 601.
19. Crafoord C (1955) Discussion on mitral stenosis and mitral insufficiency Lam CR, editor. *Proceedings of the International Symposium on Cardiovascular Surgery*, Henry Ford Hospital, WB Saunders, Detroit, Philadelphia.
20. Bahnon HT, Newman EV (1953) Diagnosis and surgical removal of intracavity myxoma of the right atrium. *Bull Johns Hopkins Hosp* 3: 150.
21. Bigelow WG, Dolon FG, Campbell FW (1955) Effect of hypothermia upon risk of surgery. *XVII Congress Internat de Chirurgie*, Copenhagen.
22. Coates EO, Jr, Drake EH (1958) Myxoma of the right atrium with variable right to left shunt: Clinical and physiologic observations and report of a case with successful operative removal. *N Engl J Med* 259: 165.
23. Tiraboschi R, Terzi A, Merlo M, Procopio A (2000) Left atrial myxoma. Clinical and surgical features in 26 surgically treated cases. *Ital Heart J* 1: 797-802.
24. Singh PK, Sureka RK, Sharma AK, Bhuyan S, Gupta V (2003) Recurrent stroke in a case of left atrial myxoma masquerading vasculitis. *J Assoc Physicians India* 61: 917-20.
25. Rajpal RS, Leibsohn JA, Liekweg WG, Gross CM, Olinger GN, et al. (1979) Infected left atrial myxoma with bacteremia simulating infective endocarditis. *ArchIntern Med* 139: 1176-1178.
26. Carney JA, Gordon H, Carpenter PC, Shenoy BV, Go VL (1985) The complex of myxomas, spotty pigmentation, and endocrine overactivity. *Medicine (Baltimore)* 64: 270-83.
27. Farah MG (1994) Familial cardiac myxoma. A study of relatives of patients with myxoma. *Chest* 105: 65-8.
28. Neau JP, Rosolacci T, Pin JC, Agbo C, Aubert I, et al. (1993) Cerebral infarction, cardiac myxoma and lentiginosis. *Rev Neurol* 149: 289-291.
29. Fuwa S, Saeki S, Shinohara A, Kataka H, Naito K, Hirose H, et al. (1991) A case of left atrial myxoma in the elderly (77-year-old). *Kokyu To Junkan* 39: 399-401.
30. Talmor D, Caspi J, Feuering S, Zuker N, Zalstein E, et al. (1996) Surgical treatment of right ventricular myxoma in infancy. *Ann Thorac Surg* 61: 1835-1836.
31. Owers CE, Vaughan P, Braidley PC, Wilkinson GA, Locke TJ, et al. (2011) Atrial myxomas: a single unit's experience in the modern era. *Heart Surg Forum* 14: E105-9.
32. Baikoussis NG, Papakonstantinou NA, Dedeilias P, Argiriou M, Apostolakis E, et al. (2015) Cardiac tumors: a retrospective multicenter institutional study. *J BUON* 20: 1115-23.
33. Zeebregts CJ, Schepens MA, Knaepen PJ (1998) Extended verticaltransatrial septal approach for the removal of left atrial myxoma. *Eur J Cardiothorac Surg* 13: 90-93.
34. Bauer EP, von Segesser LK, Carrel T, Laske A, Turina MI (1991) Early results following surgical treatment of heart tumors. *Schweiz Med Wochenschr* 21: 255-258.
35. Verkkala K, Kupari M, Maamies T (1989) Primary cardiac tumours-operative treatment of 20 patients. *Thorac Cardiovasc Surg* 37: 361-364.